

POLIPI DEL COLON

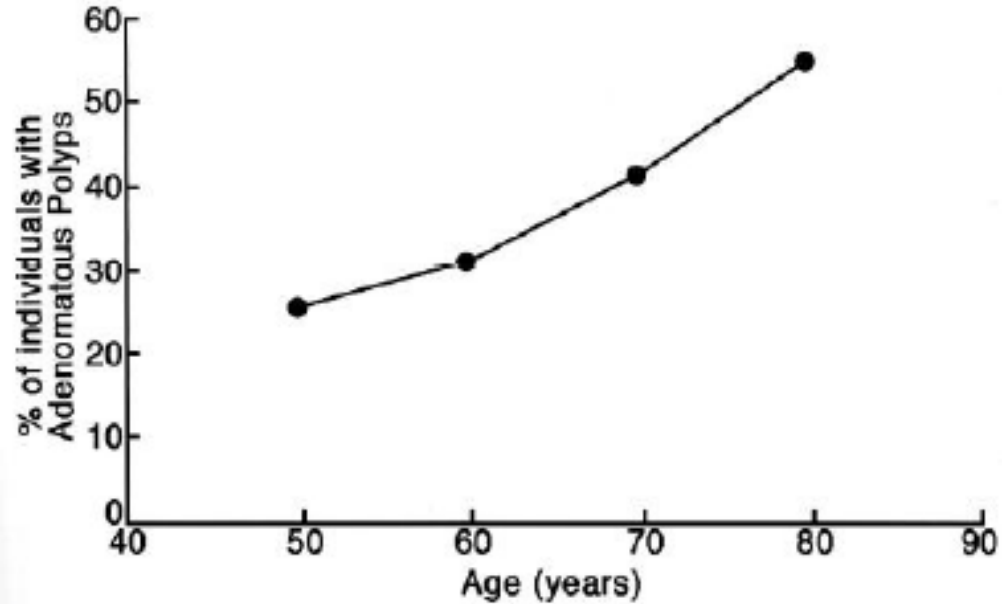
Oltre il 90% degli adenocarcinomi del colon derivano da un polipo

POLIPI DEL COLON

Classificazione istologica dei polipi epiteliali del colon retto

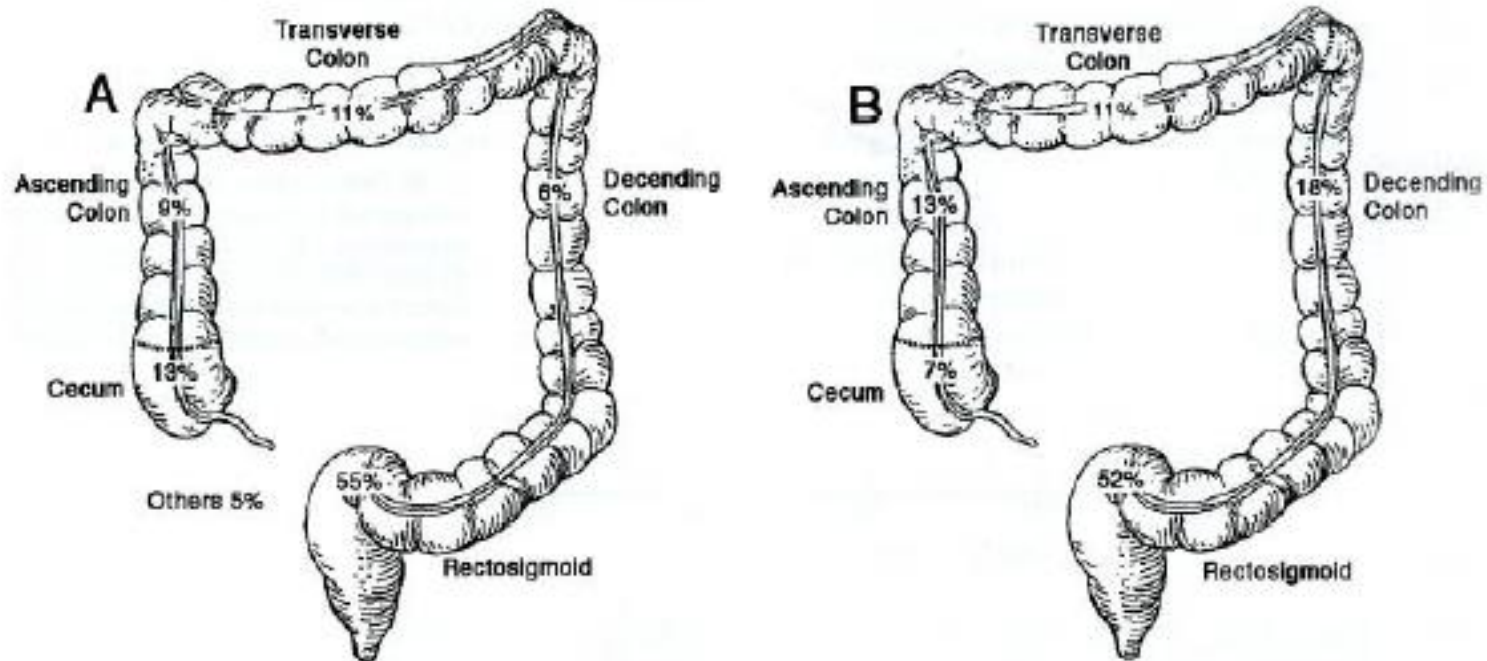
natura	tipo	sindrome poliposa
sconosciuta	polipo iperplastico	poliposi iperplastica
neoplastica	adenoma tubulare adenoma villosa adenoma tubulo-villosa adenoma serrato	FAP "s. da adenomi multipli "
amartomatosa	polipo giovanile p. di Peutz-Jeghers	poliposi giovanile s. di Peutz-Jeghers s. di Cowden
infiammatoria	polipo infiammatorio	poliposi infiammatoria

POLIPI DEL COLON



Distribuzione per età e prevalenza degli adenomi coloretali
(Winawer et al, Gastroenterology 1977;112:606)

POLIPI DEL COLON



DISTRIBUTION OF COLORECTAL CARCINOMAS AND ADENOMAS BY SITE

Left: Carcinomas.

Right: Adenomas. (Fig. 8 from Winawer SJ, Fletcher RH, Miller L, et al. Colorectal cancer screening: clinical guidelines and rationale. *Gastroenterology* 1997;112:607.)

POLIPI DEL COLON

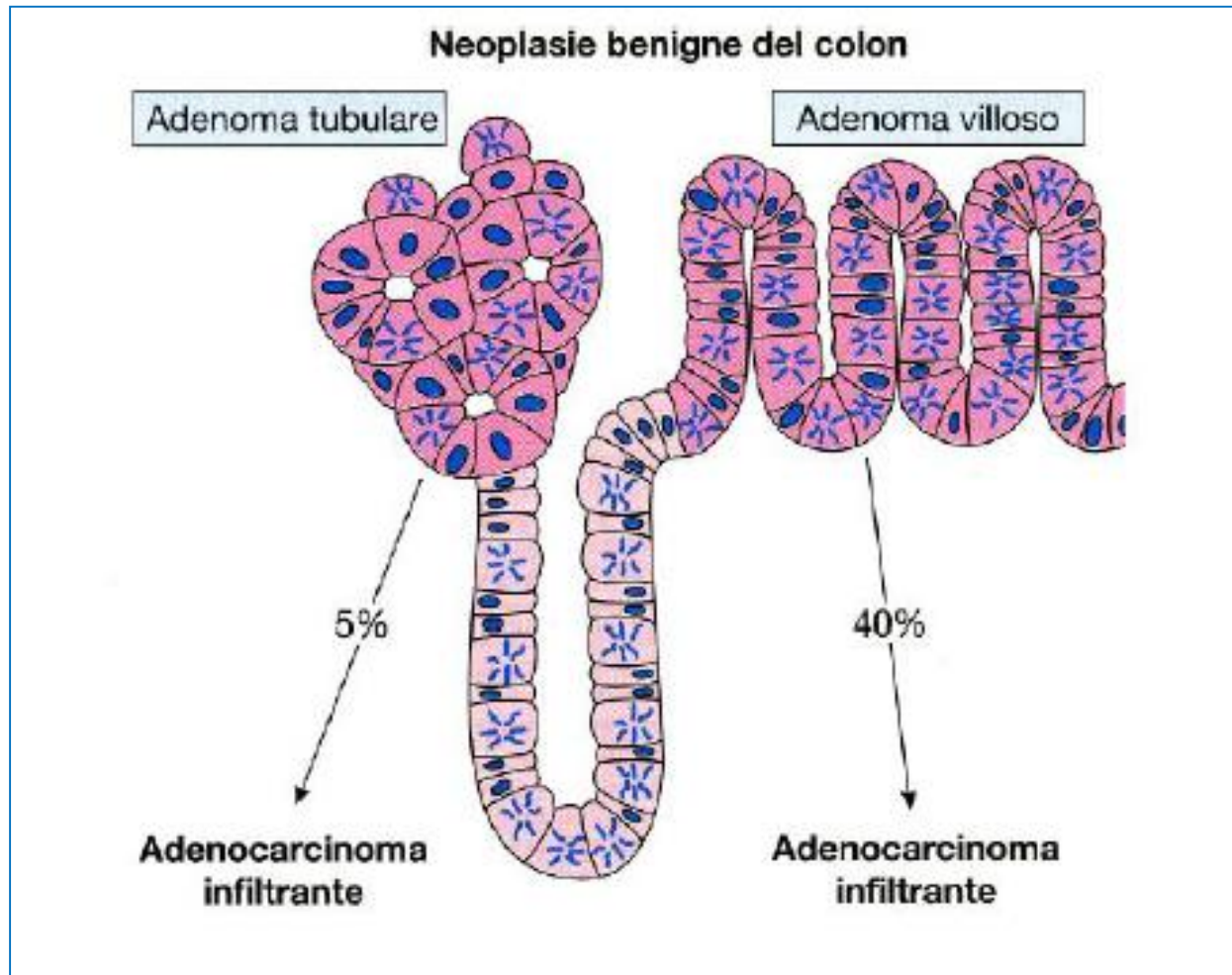
- **Istotipo**

- **Tubulare**: architettura tubulare > 80%
- **Villoso**: architettura villosa > 80%
- **Tubulo-villoso**: ciascuna delle due componenti < 80%
- **Adenoma serrato**

- **Displasia**

- **Displasia di basso grado** (displasia lieve e moderata)
- **Displasia di alto grado** (displasia grave)









POLIPI DEL COLON



POLIPI DEL COLON

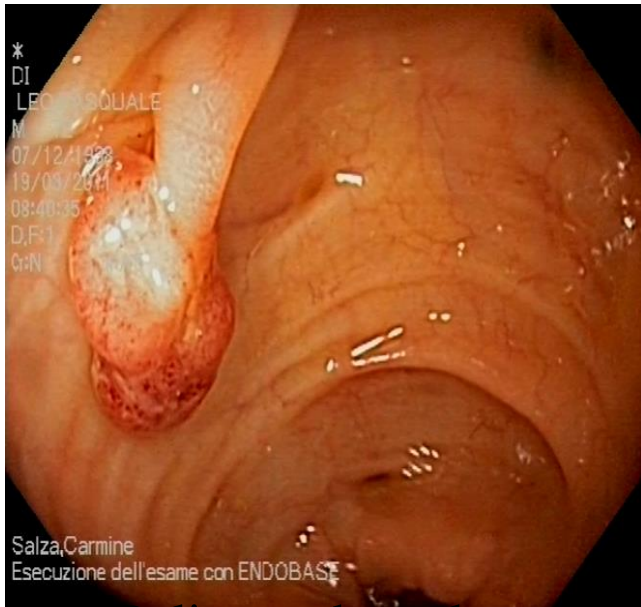Vienna Classification of Gastrointestinal Epithelial Neoplasia	
Cat 1	No dysplasia
Cat 2	Indefinite for dysplasia
Cat 3	Low grade intraepithelial neoplasia
Cat 4	High grade intraepithelial neoplasia (HGIN)
Cat 51	Invasive epithelial neoplasia Invading lamina pr. or m.m.
Cat 52	Invasive epithelial neoplasia Invading submucosa

POLIPI DEL COLON

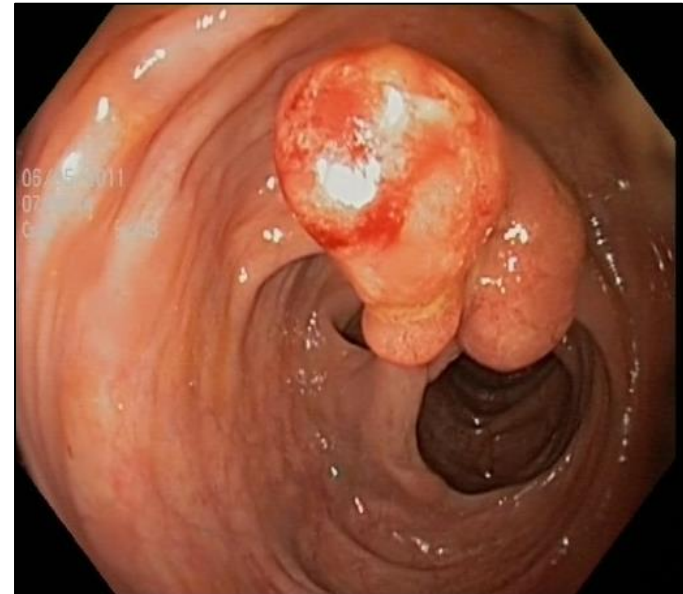
Endoscopic appearance	JRSC class		Description
Protruded lesions	Ip		Pedunculated polyps
	Ips		Subpedunculated polyps
	Is		Sessile polyps
Flat elevated lesions	Ila		Flat elevation of mucosa
	Ila / Ile		Flat elevation with central depression
Flat lesions	Ilb		Flat mucosal change
	Ile		Mucosal depression
	Ile / Ila		Mucosal depression with raised edge

Classificazione endoscopico-morfologica
lesioni superficiali Parigi 2002

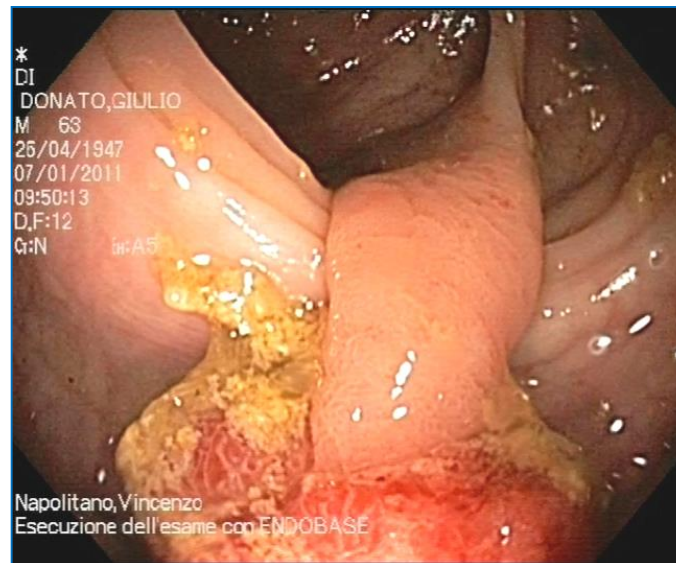
POLIPI PEDUNCOLATI



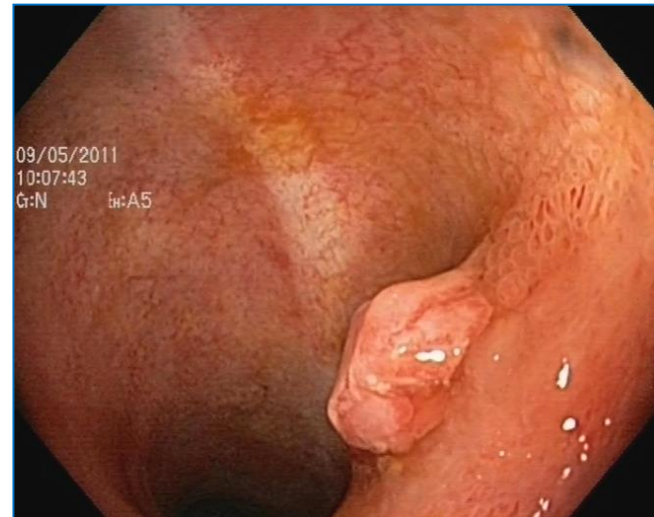
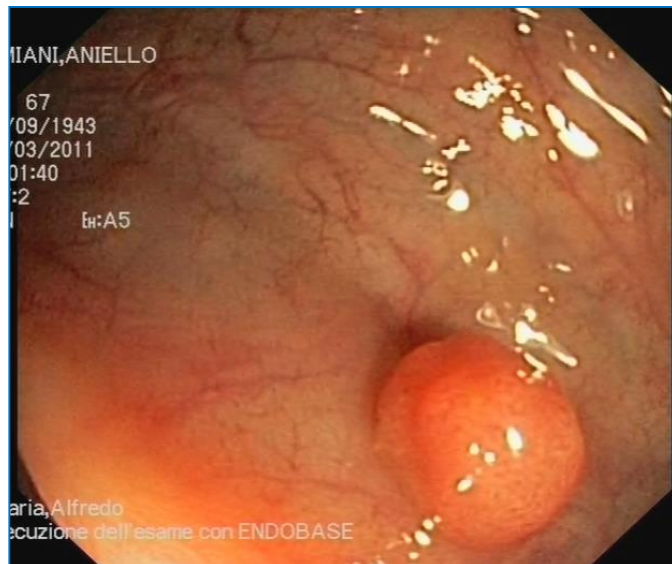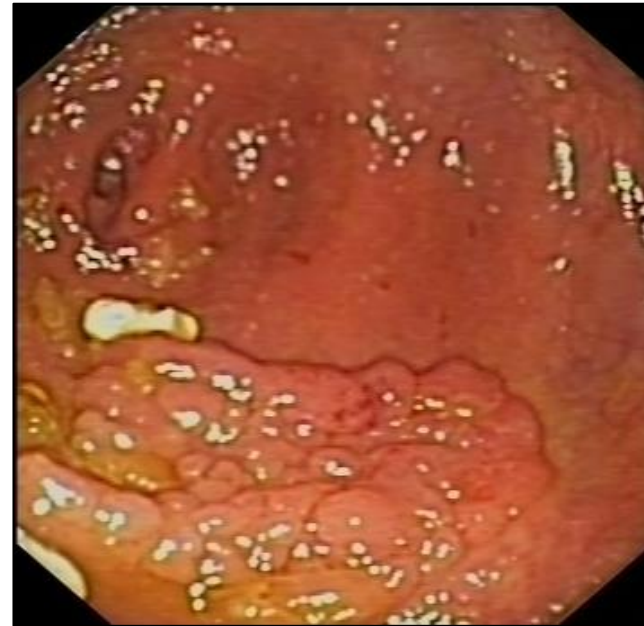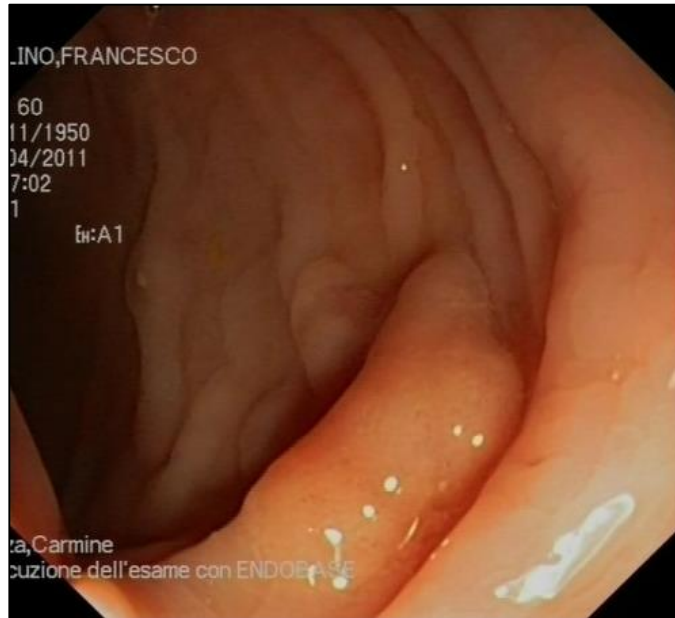
Polipo peduncolato



Polipo con corto peduncolo

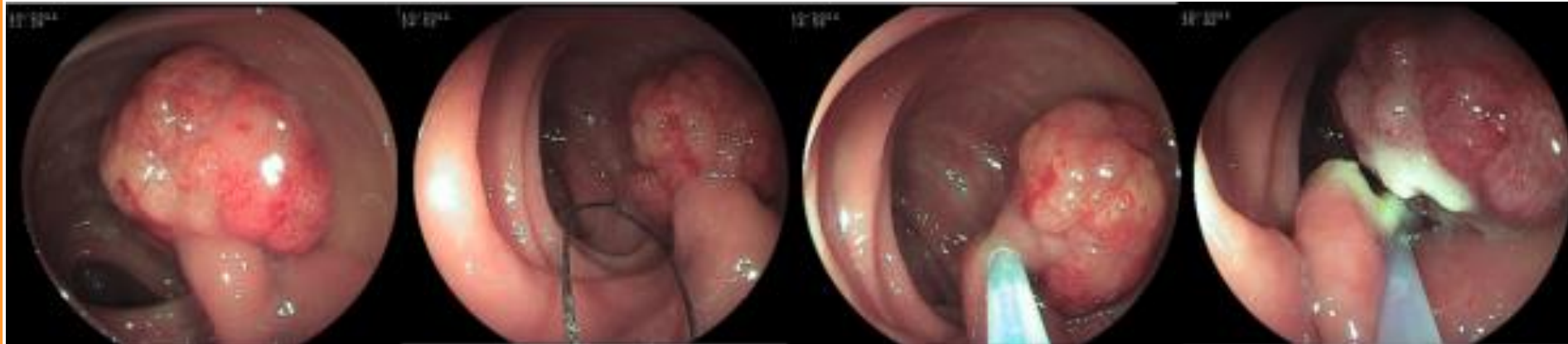
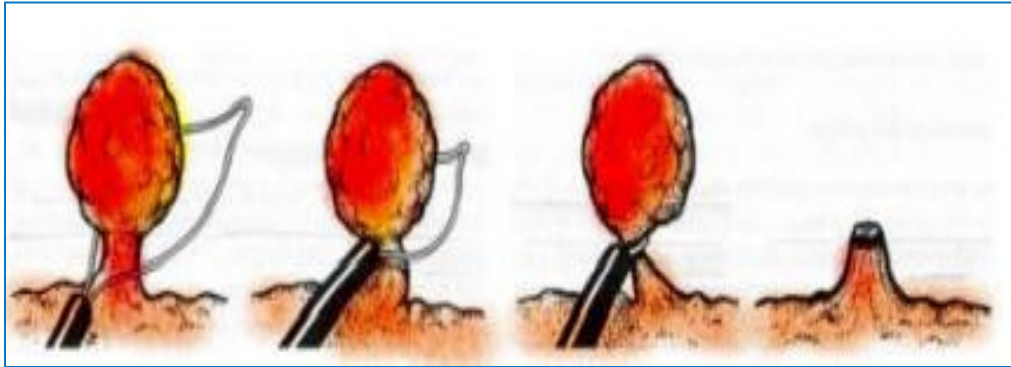


POLIPI SESSILI



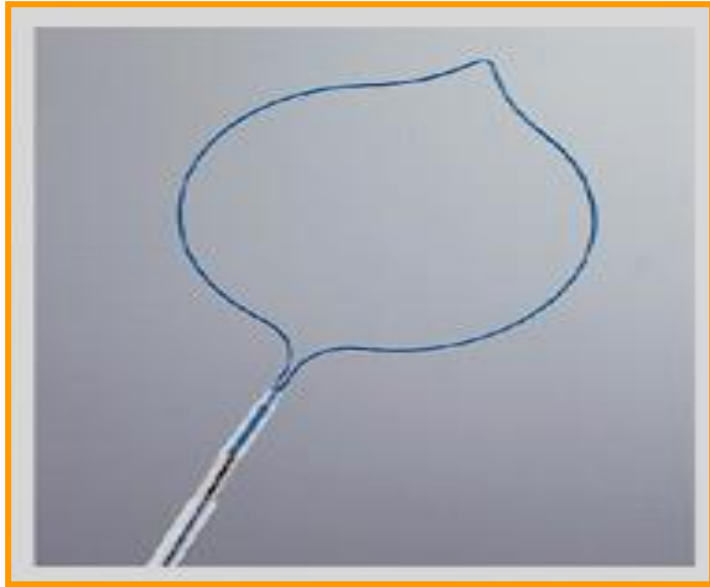Polipectomia di polipi peduncolati

Ansa diatermica

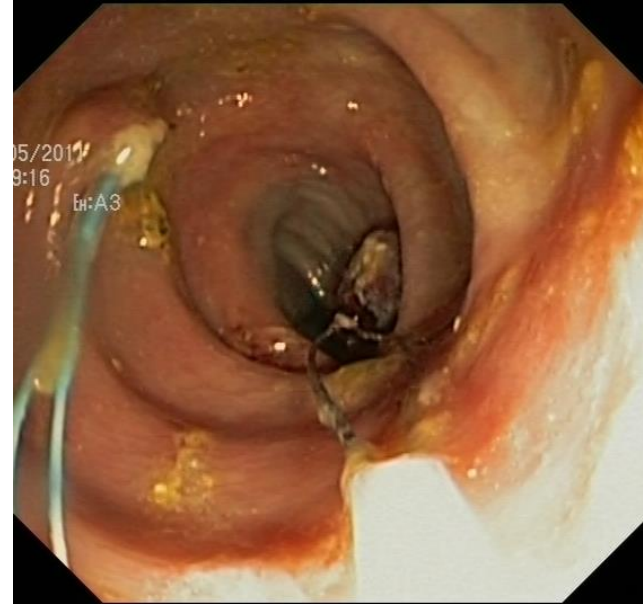


Polipectomia di polipi peduncolati

polipi con tozzo peduncolo: Uso dell'endo loop



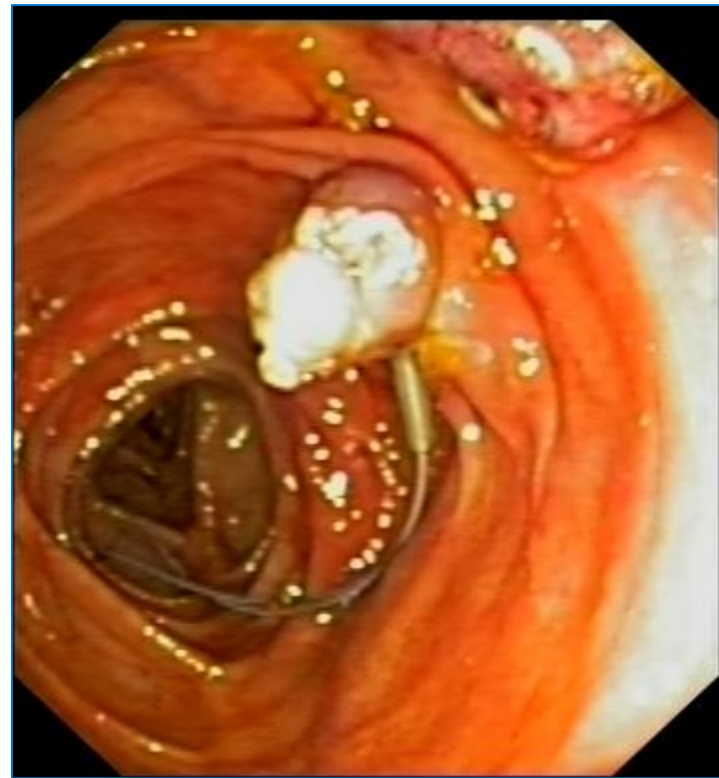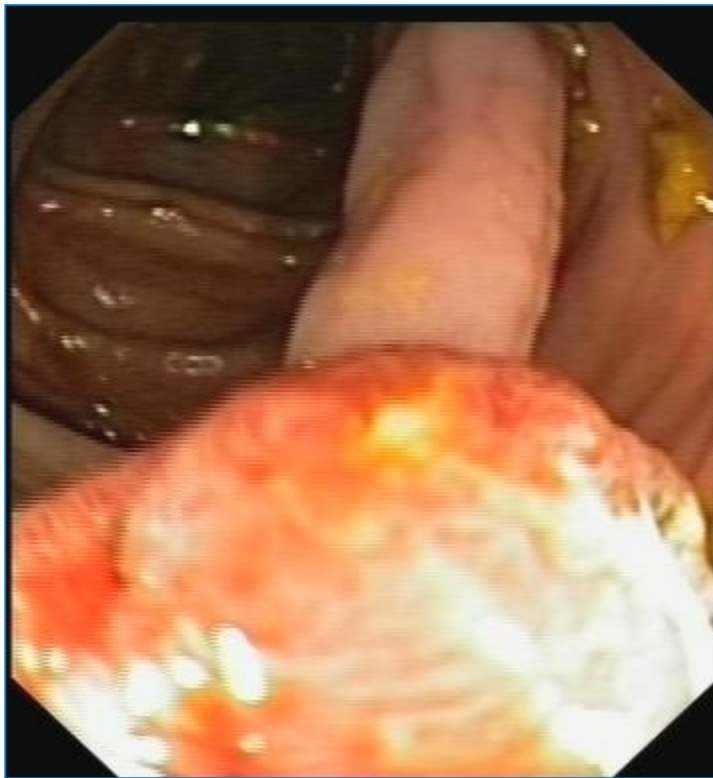
Endo- loop



Endo- loop stretto intorno alla base del polipo

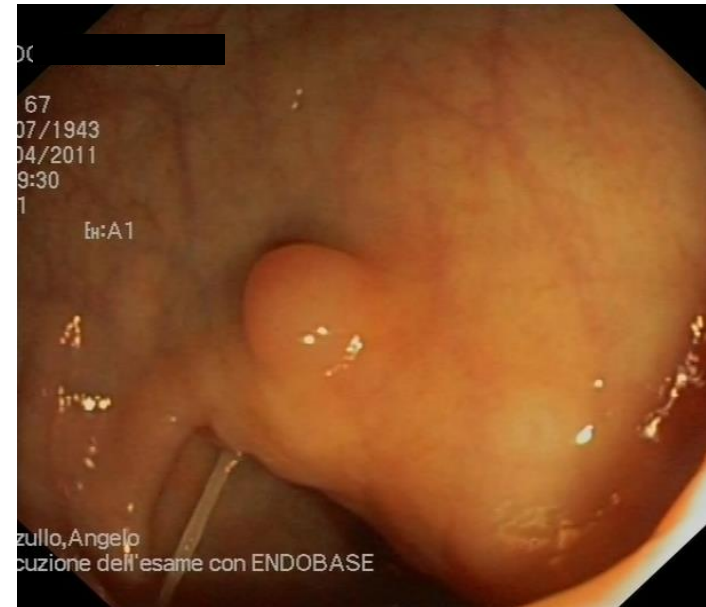Polipectomia di polipi peduncolati

polipi con tozzo peduncolo: Uso dell'endo loop



Polipectomia di polipi sessili

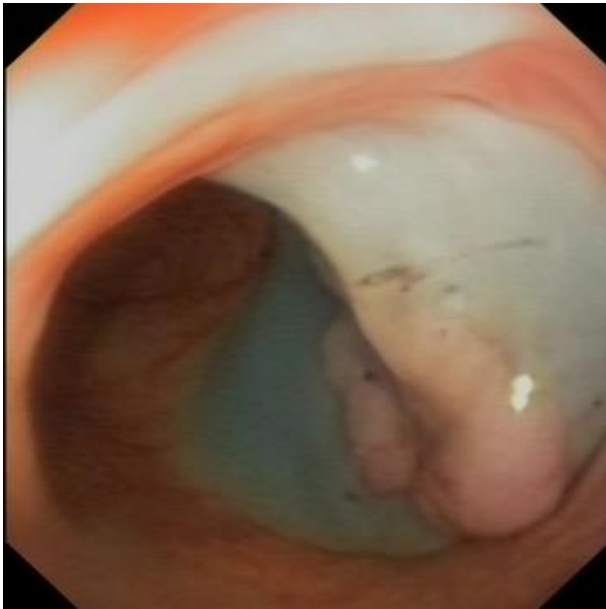polipectomia con pinza a freddo



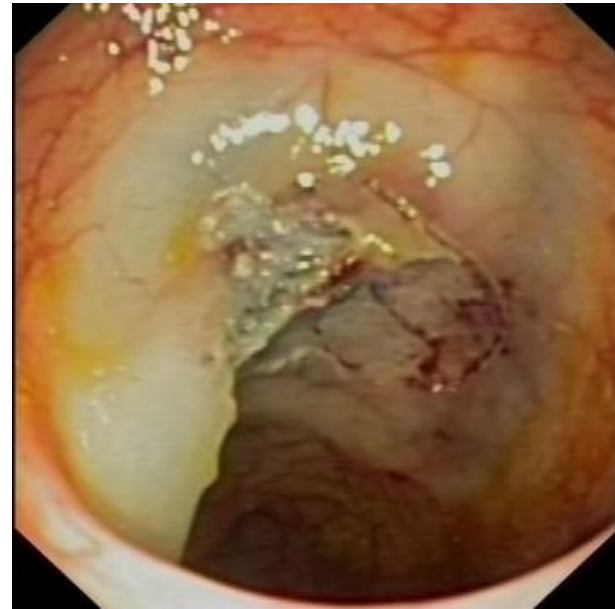Piccolo polipo sessile

Polipectomia di polipi sessili

polipectomia previo lifting



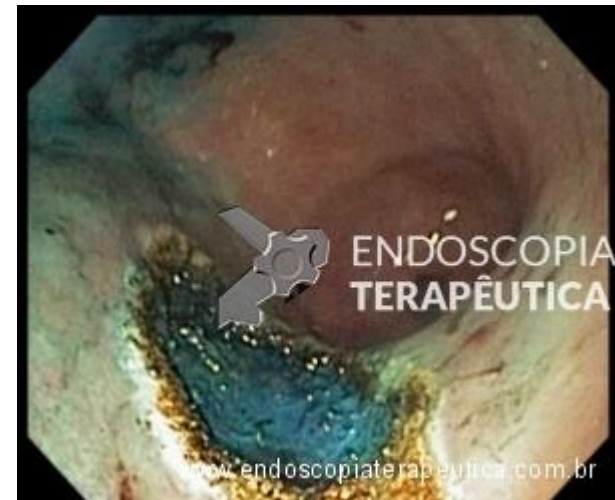
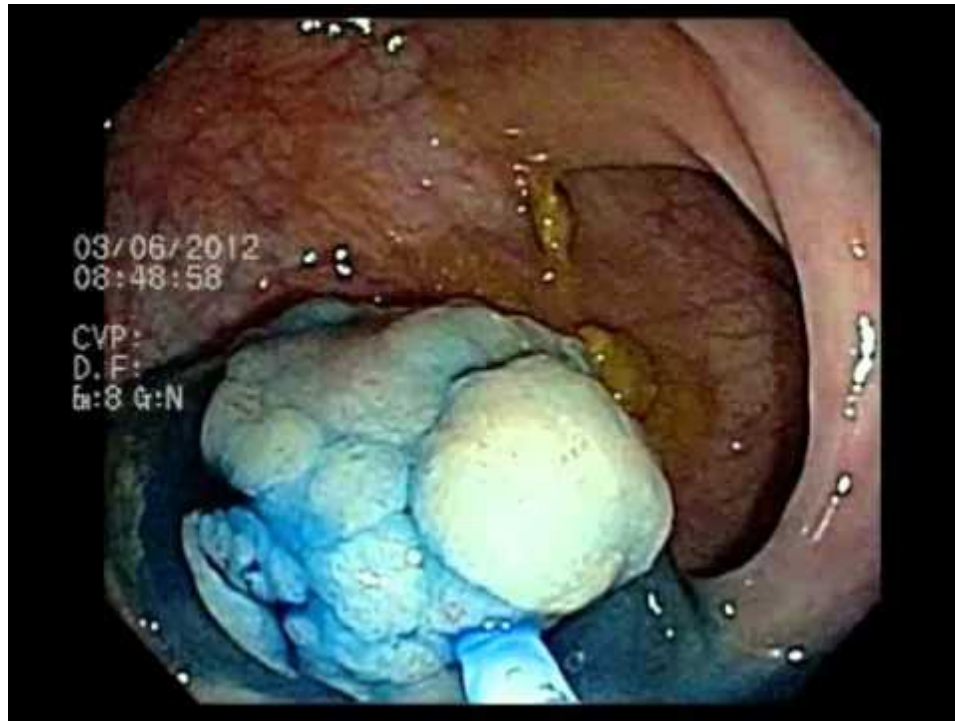
Scollamento del polipo sessile
mediante infiltrazione sottomucosa
“lifting”



Quadro dopo l'asportazione
del polipo

Polipectomia di polipi sessili

polipectomia previo lifting



POLIPI DEL COLON

Polipectomia

Complicanze

- Emorragia
- Perforazione